

# Diagnosing Small Fiber Neuropathy Through the Use of Skin Biopsy

A simple test can easily determine the presence of small fiber neuropathy. Here's what you need to know.

By David S. Saperstein, MD and Todd D. Levine, MD

**N**europathic pain is one of the most common reasons for a patient to seek medical attention. Despite the utility of electromyography, nerve conduction studies, quantitative sensory testing, and extensive serologic evaluations, many patients with neuropathic pain have no identifiable abnormalities on these tests. In such patients the question of a neuropathy affecting only the small sensory nerve should be entertained. However, until recently there has been no practical confirmatory test for small fiber neuropathy (SFN). In the last few years, quantification of small nerve fibers in skin punch biopsies has emerged as a readily available means for confirming the diagnosis of SFN. This simple punch biopsy is a straight-forward and patient friendly test with a high diagnostic yield in the clinical setting.

Yet, some clinicians are reluctant to perform skin biopsies to test for small fiber neuropathies because they are unfamiliar with the process and its easy integration into practice or are unaware that the results of testing can help direct the treat-

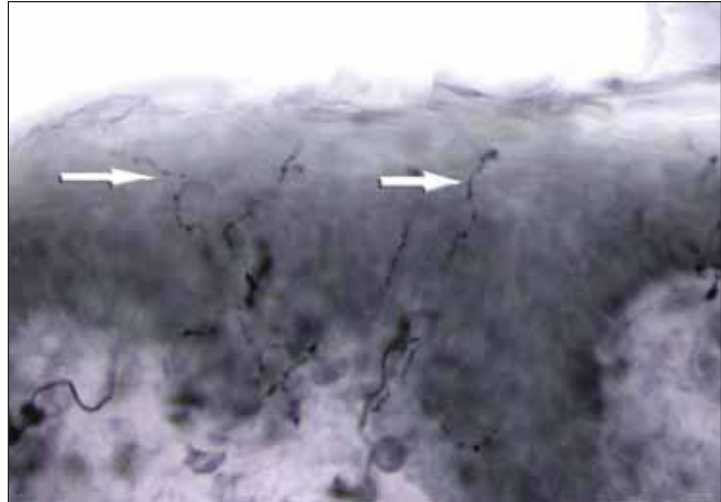


Fig. 1. Skin biopsy from the upper thigh showing normal epidermal nerve fibers (arrows).

ment course. This article will review the role of skin biopsy, highlighting the potential value of this test to clinicians.

## Nerve Fiber Size – A Brief Review

Nerves are composed of fibers that vary in size and function. The larger, myelinated A-alpha and

## Small Fiber Neuropathy

A-beta fibers convey proprioception and touch. The small fibers consist of the myelinated A-delta and unmyelinated C fibers, which convey pain and temperature. Most peripheral neuropathies affect nerve fibers of all sizes. Such neuropathies are referred to as mixed fiber neuropathies (MFN). In rare cases, only the largest fibers (A-alpha and A-beta) are affected. In these large fiber neuropathies, impaired proprioception is the main deficit. More common than large fiber neuropathies, but less common than MFN, are SFN wherein only the A-delta and C fibers are involved. Patients with SFN can be difficult to diagnose, as they can present with many atypical complaints and a paucity of objective findings on exam.

### Diagnosing SFN

Patients with SFN typically present with numbness, paresthesias, and pain. Pain tends to be a prominent symptom and often has a burning quality. However, there are no unique features of the pain that can, by themselves, distinguish patients with SFN from those with other neuropathies.<sup>1</sup> In most cases of SFN, the distribution and character of sensory symptoms and findings will resemble those seen in patients with MFN: symmetrical, length-dependent, and persistent. However, a number of SFN patients will manifest atypical features, such as non-length-dependent, multifocal numbness that may come and go.<sup>2,3</sup> These unusual features can often lead to a misconception that the patient's pain is not organic. This fact highlights the benefits of having a readily available test to objectively

prove that a SFN exists in these patients before dismissing them as functional.

Evidence that the neuropathic symptoms are due to isolated involvement of the small nerves comes from a neurological examination revealing preserved deep tendon reflexes, vibratory sensation, and proprioception. Soft touch or pinprick sensation may be slightly reduced but is rarely dramatically affected.

The test that is most useful in diagnosing mixed fiber peripheral neuropathies—nerve conduction studies (NCS)—is normal in SFN. However, whether or not NCS are normal may depend on which tests are performed. Testing plantar nerve sensory responses may indicate a mild, distal MFN in a number of patients who have normal sural responses.<sup>4</sup> Biopsy of a cutaneous nerve, such as a sural nerve, can confirm SFN. However, this is an invasive procedure that will leave a permanent area of sensory deficit in a patient who typically has otherwise mild sensory deficits. In addition, quantification of small nerve fibers in a sural nerve biopsy is not routinely available from most pathology laboratories.

Some patients with SFN also have a concomitant autonomic neuropathy, and therefore autonomic nervous system testing can provide objective confirmation in some cases.<sup>5,6</sup> Although certain aspects of autonomic function can be assessed by measuring heart rate and blood pressure responses, the most sensitive tests for SFN involve assessment of sudomotor function. Quantitative sudomotor axon reflex testing (QSART) is a useful, noninvasive test. However, access to a facility offering QSART testing is very limited. Quantitative sensory testing (QST), another noninvasive test, can also support a diagnosis of SFN. However, this test is not entirely objective and, like QSART, is not widely available.

### Skin Biopsy for Quantification of Epidermal Nerves

Techniques to identify small fiber neuropathy using skin biopsies have been available at several academic centers for many years, but this procedure has become commercially assessable to prac-

#### Nerve Fibers and Functions

Fibers	Size	Function
Myelinated A-alpha and Myelinated A-beta fibers	Large	Proprioception and touch
Myelinated A-delta and Unmyelinated C fibers	Small	Pain and temperature

tioners only recently. Three millimeter skin punch biopsies are processed for immunohistochemical staining with antibodies against protein-gene product (PGP) 9.5, a pan-axonal marker. This allows visualization and quantification of unmyelinated C-fibers and possibly myelinated A-delta fibers, in the epidermis (Fig. 1). If the density of epidermal nerve fibers is decreased, as compared to established normative data, then a diagnosis of SFN is supported.

The commonly used normal values provide for a high specificity, but the precise sensitivity of this test is uncertain due to the lack of a gold standard. Using current normal values, epidermal nerve fiber density is abnormally decreased in only about two-thirds of patients suspected of having SFN.<sup>3,4,6</sup> Therefore, a normal skin biopsy does not exclude SFN.

The biopsy technique to obtain the skin samples is easily learned and can be performed quickly. A 3mm circular punch is used. The only pain is that resulting from injection of lidocaine. The wound can be dressed with a simple band-aid and there is minimal scarring. Samples are typically acquired from two or three standardized sites (such as lower calf, distal thigh, and proximal thigh). It is usually sufficient to obtain biopsies from only a single limb. Having proximal and distal biopsy sites helps determine whether a neuropathy is length-dependent or not (non-length dependant findings would support a diagnosis of a ganglionopathy as opposed to a neuropathy, as is seen in Sjögren syndrome and some paraneoplastic diseases). Specimens are placed in a vial with fixative and can be sent via overnight shipping to a commercial laboratory. Results are generally available within two weeks.

Skin biopsy is a low-risk procedure that any clinician can easily learn to perform. In fact, several commercial laboratories that process the specimens provide video demonstrations, most of which are available online, along with illustrated guides to the biopsy procedure. Reimbursement for performing the biopsies is reasonable.

Nonetheless, it seems that many clinicians are

not ordering this test. Some may not recognize that this testing is readily available, while others may not appreciate the potential benefits of a biopsy-confirmed diagnosis of SFN.

### **Benefits of a Confirmed Diagnosis**

Prior to the availability of the epidermal biopsy technique, the diagnosis of SFN was largely one of exclusion. In many cases, it may be unclear whether a patient has a SFN versus some other pain syndrome, such as fibromyalgia. Admittedly, symptomatic treatment strategies would be largely the same regardless of diagnosis. For this reason, a number of clinicians may argue against the utility of performing a skin biopsy. In some cases, this is a valid argument. However, there are situations in which it is unclear whether a patient has a SFN as opposed to non-neurological process or even a somatization disorder. In some of these circumstances, knowing the precise diagnosis will affect treatment, determining, for example, how aggressively the patient will be treated or whether the neurologist will refer the patient to another provider, such as pain specialist, podiatrist, or psychiatrist.

There is a sizable subset of SFN patients who present with non length-dependent or multifocal symptoms. Some patients with biopsy-confirmed SFN will report sensory symptoms that come and go and may have normal examinations. It is these patients in whom we find skin biopsy to be an extremely helpful test. We have been surprised a number of times to find abnormal biopsies in patients whom we suspected had psychogenic or podiatric processes. There are also cases where symptoms raise the question of a central nervous system process. Confirming SFN with skin biopsy can eliminate the need for other testing.

Even in patients with a clinical picture quite suggestive of SFN, skin biopsy may have utility. We recently reviewed the records of 145 patients in our practice who underwent a skin biopsy for suspected SFN between January 2005 and June 2008. Patients with abnormal nerve conduction studies or evidence on neurologic exam of a medi-

um or large fiber neuropathy were excluded from the analysis. Patients with an abnormal skin biopsy were more than twice as likely to respond to a first-line neuropathic pain medication compared to patients with normal biopsies.<sup>3</sup>

### Management of Confirmed SFN

The epidermal biopsy technique is intended only to confirm diagnosis of SFN. Unlike sural nerve biopsy, which is usually performed to identify the etiology of neuropathy (such as vasculitis, CIDP, or amyloidosis), skin biopsy will seldom disclose an etiology. In rare cases, skin biopsy may provide evidence for vasculitis or amyloidosis. However, this procedure is not able to “rule out” these possibilities.

Also, an abnormal skin biopsy does not necessarily mean the patient has a pure SFN. Epidermal nerve fiber density will be decreased in patients with a mixed fiber neuropathy. Only when MFN has been excluded on the basis of examination and NCS can the finding of decreased epidermal nerve fiber density be used to impute a diagnosis of SFN.

More than half of SFN cases will be idiopathic.<sup>1,3,4</sup> Some potentially treatable causes include Sjögren syndrome and vitamin B12 deficiency. Many patients will have diabetes or impaired glucose tolerance; chemotherapy, monoclonal gammopathy and alcohol abuse are other potential causes.<sup>1,3,4</sup>

The main therapeutic intervention in patients with SFN is symptomatic treatment for neuropathic pain. As noted above, standard first-line therapies (such as duloxetine (Cymbalta, Lilly), pregabalin (Lyrica, Pfizer), and gabapentin (Neurontin, Pfizer)) have proven useful. Additional treatment options include other antiseizure and antidepressant medications. Many patients with SFN will not tolerate or will not get relief from these medications.

Sustained-release opiates may be appropriate for some patients. While data are not available for SFN specifically, there is evidence to support the use of opiates in patients with other peripheral neuropathies.<sup>7</sup> Before utilizing opiates, it is helpful

to have a biopsy-confirmed diagnosis of SFN. Neurologists who are uncomfortable prescribing opiate analgesics may consider referring potential candidates to a pain specialist or may implement measures to help ensure the safe use of opiates and minimize the risk of abuse. Such measures have been described in other publications and guidance is available from specialty organizations (such as the American Pain Society, [ampainsoc.org](http://ampainsoc.org)).

### A Beneficial Tool

SFN may be an underdiagnosed condition. Historically a diagnosis of exclusion, SFN can now be confirmed through a skin biopsy. Confirming the diagnosis may allow the clinician to more efficiently institute therapy and evaluate possible underlying etiologies. The biopsy technique is straightforward, easily learned, widely available, and relatively inexpensive. It is patient-friendly, relatively pain-free, and provides a high diagnostic yield. ■

*Todd D. Levine, MD, Phoenix Neurological Associates, Ltd., Assistant Professor of Clinical Neurology, University of Arizona in Phoenix.*

*David S. Saperstein, MD, Phoenix Neurological Associates, Ltd., Clinical Associate Professor, Department of Neurology, University of Arizona in Phoenix.*

1. Devigili G, Tugnoli V, Penza P, Camozzi F, Lombardi R, Melli G, Broglio L, Granieri E, Lauria G. The diagnostic criteria for small fibre neuropathy: from symptoms to neuropathology. *Brain*. 2008;131:1912-25.
2. Gorson KC, Herrmann DN, Thiagarajan R, Brannagan TH, Chin RL, Kinsella LJ, Ropper AH. Non-length dependent small fibre neuropathy/ganglionopathy. *J Neurol Neurosurg Psychiatry*. 2008;79:163-9.
3. Levine T, Levine M, Hank N, Saperstein DS. Retrospective Assessment of the Usefulness of Skin Biopsies in the Evaluation and Management of Patients with Suspected Small Fiber Neuropathy. *Neurology* 2009; 72 (Suppl 3):A56-57.
4. Herrmann DN, Ferguson ML, Pannoni V, et al. The Plantar Nerve AP and Skin Biopsy in sensory neuropathies with normal routine conduction studies. *Neurology* 2004; 63:879-85
5. Stewart JD, Low PA, Fealey RD. Distal small fiber neuropathy: results of test of sweating and autonomic cardiovascular reflexes. *Muscle Nerve* 1992; 15:661-665.
6. Periquet I, Novak V, Collins M, et al. Painful sensory neuropathy; prospective evaluation using skin biopsy. *Neurology* 1999; 53:1641-1647.
7. Gimbel JS, Richards P, Portenoy RK. Controlled-release oxycodone for pain in diabetic neuropathy: a randomized controlled study. *Neurology* 2003;60:927-934.